READ ME FOR CPD

Peri-implantitis: from diagnosis to treatment

By Dr Magda Mensi, DDS and Dr Annamaria Sordillo, DDS

PERI-IMPLANT disease diagnosis is as fundamental as it is controversial. Although progress has been made during the last few decades, it's still hard to find an univocal set of definitions and diagnostic criteria.[1-3] The parameters used to define peri-implant disease usually are as follows: Probing Depth (PD), Crestal Bone Loss (CBL), Bleeding on Probing (BOP) and the presence of suppuration and/or fistula.[4] Peri-implant mucositis is characterised by the inflammation of the soft tissues, detectable by means of BOP, with or without PD deepening, but having no effects on the crestal bone. Conversely, peri-implantitis is characterised by CBL and BOP, alone or in conjunction with PD deepening and pus. Figures 1-3 display the diagnostic steps of a case of peri-implantitis. While mucositis can be cured, peri-implantitis damages are irreversible.[5]

PD sets the first controversial point in diagnosis: the sulcus around implants can be considered surgically created since it corresponds with the deepness of the implant positioning, the quantity of soft tissue and the length of the abutments. Given this, we cannot easily draw a line between "health" and "disease" PD for implants as we do for natural teeth.[6] Since the deepening of PD has proved to be a predictive factor of disease development, it's logical to index baseline PD to detect any possible change.[2,6]

Crestal Bone Loss is also an ambiguous point because a change in the marginal bone level is known to occur after every implant placement and restoration.[7] It's necessary to agree on a baseline for the radiographic evaluation of bone level changes and set an acceptable bone loss rate. Based on longitudinal clinical studies, it's rational to choose the time of prosthesis installation as a reference from which the disease can be diagnosed and monitored.[2] Based on an Albrektson and Zarb review, the success criteria are as follows: 1.5mm of bone loss in the first year and less than 0.2mm annually.[7] A CBL exceeding this rate puts the implant at risk of failure. Although, x-rays display just interproximal bone, being other areas overlapping the implant itself. Probing remains the only way to evaluate buccal/lingual tissues level.

Challenges in diagnosing peri-implantitis

Bleeding on Probing is the critical parameter for peri-implant disease diagnosis.[8] Presence of BOP can be found in 91% of implants with peri-implantitis and its absence is regarded as a reliable predictive parameter of implant health.[5]

An appropriate diagnosis can only be given if probing is possible. Incorrect positioning, implant and abutment design (e.g. platform switching), lack of surface smoothness, over-contouring and the extension of suprastructures may impair probing and create the risk of disease underestimation.[2,6] Underestimation of PD can lead to underestimation of CBL.[9] If undiagnosed, peri-implantitis may lead to the complete failure of osteointegration and implant loss.[5] The epidemiology is not comforting: in a recent systematic review the authors reported that 43% of the implants included in the meta-analysis were affected by mucositis and 22% by peri-implantitis.[10]

Preventing peri-implantitis

Peri-implantitis lesions are different from periodontitis, both in terms of size and composition of the inflammatory infiltrate.[11] Peri-implantitis lesions are known to progress faster[2] and have a more uncertain response to both surgical and non-surgical treatments.[12]

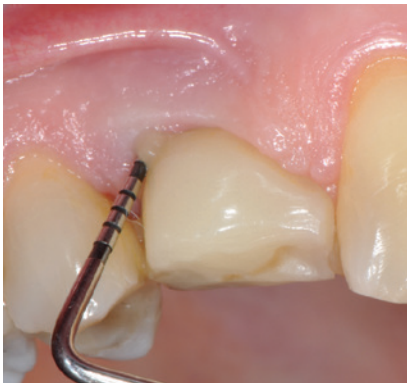

Figure 1. Case 1 - Peri-implant probing reveals a PPD of 9mm and pus.

Figure 2. Case 1 - BOP starts immediately after probing.

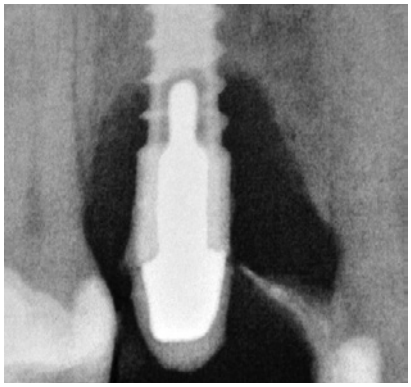

Figure 3. Case 1 - X-ray showing severe peri-implant CBL.

Figure 4. Case 1 - Clinical appearance after the prosthetic crown removal.

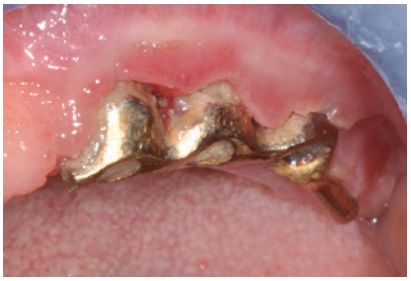

Figure 5. Implant bar with abundant plaque deposits and evident mucositis.

Figure 6. Resolution of mucositis after non-surgical therapy and healing period without bar.

This is enough to confirm that prevention is of major importance for the success of implant restorations. Prevention begins with putting the patients into risk categories.[8] Subjects with a history of periodontitis are at a greater risk to develop MBL and peri-implantitis.[5] This risk is also increased in cases of rough implants, poor oral hygiene, smoking, diabetes and poor metabolic control.[2,5,13] Clinicians must be able to diagnose and treat periodontal disease and to motivate and educate patients to improve not only the health of their implants but also their overall health.[8]

The second step of peri-implantitis prevention can be carried out during the surgical phase. The correct positioning of the fixture helps the technician in constructing the prosthesis, the Periodontist in checking the health of the implant, the hygienist in cleaning the peri-implant area effectively[8] and the patient in keeping a high standard of home-care. Ineffective care leads to the development of inflammatory reactions that can be hidden under the prosthesis and not revealed until the prosthesis is removed. (Figure 4). Particular attention should be given to reach an appropriate amount of keratinized peri-implant tissue: its presence can be beneficial to oral hygiene practices.[8] From a periodontal point of view, long abutments and implant placement at a sub-mucosal level are considered a poor choice. This is due to the deep probing depth created since the implant placement.[8]

The third step of peri-implantitis prevention is Supportive Periodontal Therapy (SPT): the lack of regular and effective SPT is a risk factor for the development of peri-implantitis.[13] Every recall appointment should be accompanied by a proper examination and probing.[8] This is to detect and effectively treat any case of peri-implant mucositis since it can progress to peri-implantitis.[2] Sometimes it might be necessary to remove the overlying prosthesis to achieve a more effective treatment and in some cases, a better resolution of the inflammatory disease (Figures 5-6).

The objective of SPT should be the absence of peri-implantitis inflammation attested by the absence of BOP.

Treating peri-implantitis

But what should clinicians do in cases of peri-implantitis? Seeing peri-implantitis as an infective pathology, biofilm and calculus removal is the key.[2,8] A gold standard, non-surgical treatment still does not exist.[14] Up until now, no treatment has shown clinical advantages over others and a tendency for disease recurrence has been reported.[4]

Conventional approaches to treatment

Up to now, clinicians have been trying to treat peri-implant disease with the same instruments and strategies used for periodontal disease. The use of manual and mechanical devices may seem a suitable option to disrupt the complex peri-implant biofilm.[2,15] Unfortunately, this is disputable given the structural differences between a tooth and an implant. Scaling and root planing make little sense on a titanium surface with its particular micro and macro structure. To restore implant biocompatibility, the

surface should be decontaminated from bacteria and toxins without modifying or scratching the smooth neck nor the rough areas. Surface abrasion and the production of ions and metal particles is a miscalculated issue in dentistry. Wear debris has been described to be one of the responsible factors for aseptic loosening of orthopaedic implants.[16] Metal particles can be phagocytized by macrophages, inducing the expression of pro-inflammatory cytokines activating osteoclasts maturation.[17] On the surface of titanium implants, there is a self-repairable layer of TiO_2 with high chemical stability that prevents the diffusion of metallic ions. Scratching the implant or abutment surface could lead to the temporary removal of the TiO_2 layer and the creation of metal particles.[18] Fretwurst et al.[19] analysed bioptic samples of bone and soft tissues of patients with severe peri-implantitis. In 75% of the biopsies, it was possible to detect titanium particles accompanied by pro-inflammatory macrophages. The alteration of the oxide layer and the contamination of the surface by instrument debris results also in impaired cell adhesion and implant biocompatibility.[20,21] In some in-vitro studies, implant surface treated with stainless-steel curettes show a significantly lower number of attached fibroblast compared to untreated controls.[21] Furthermore, smooth implant surfaces scratched with mechanical instruments show increased roughness that causes the formation of more biofilm.[22]

This is the reason why alternative curette materials (titanium-coated, carbon fibre, Teflon, plastic) have been introduced in the attempt to not damage the implant surface. The same scenario has occurred with ultrasonic devices: ether-ketone-coated tips have been proposed as an efficient scaling instrument. Fox et al.[20] showed that plastic and titanium curettes produce significantly lower roughness on titanium surfaces compared to steel ones. Unfortunately, the softer the material, the more limited the debridement power. Different non-metal curettes were found to be ineffective in removing bacteria and calcified deposits from smooth as well as rough titanium surfaces.[15] They also showed a lack of flexibility which prevents the adequate cleaning of the threads. Ultrasonic scalers with non-metal tips seem to be effective in removing bacteria from smooth surfaces but show controversial results on rough surfaces.[15]

Air-polishing as an effective treatment regime

Coadjuvants and new technologies have been introduced to overcome the limitations of conventional treatment methodologies. Air-polishing devices aim to be more efficient and effective at removing biofilm. Abrasive powders are understood to be more efficient in reaching the inner part of the threads and the smallest anfractuosity, being respectful of the metal surfaces.[22] Sodium bicarbonate was proved to be suitable for biofilm removal, in particular from rough implant surfaces[15] and more effective than plastic manual and mechanical instruments, regardless of the surface characteristics.[15] The downside is that sodium bicarbonate can be harmful to soft tissues and can increase the roughness of smooth surfaces.[15] This problem has been overcome thanks to the introduction of low-abrasive powders, such as glycine and erythritol (EMS Powder PLUS®). Both are proven to be respectful of oral soft tissues.[23] Successful in-vitro results have been reported: glycine "seems" to be effective at removing biofilm from both smooth and rough surfaces.[15] Repeated use of glycine powder was not associated with any surface alterations,[15] making its use feasible for life-long implant maintenance. Schmage et al.[24] proved glycine powder to be as effective as ultrasonic instruments with PEEK-coated tips in cleaning both smooth and structured surfaces. Drago et al.[25] analysed the in-vitro effect of erythritol powder, finding stronger antimicrobial and antibacterial activity than glycine. Erythritol powder has a lower granulometry, maintaining a high cleaning potential. This may help in reaching the micro-anfractuosity of the implant and, in conjunction with the antimicrobial activity, detoxify the surface.

Schmidt et al.[26] analysed the effects of different instruments (stainless steel and plastic curettes, stainless steel and plastic-coated ultrasonic devices, two types of glycine powders and an erythritol one) on implant necks. Through a scanning electron microscope, they observed that air-polishing treatments resulted in the least surface modifications. Amongst the powders tested, erythritol was proven to be the most respectful of the implant surface.

Furthermore, the introduction of specifically designed flexible nozzles (EMS PERIFLOW®) able to reach the deeper portion of the pockets has increased the decontamination power. Ronay et al.[27] in an in-vitro study reproduced different peri-implant defect morphologies around rough implants and introduced simulated biofilm. They tested the cleaning effectiveness of a steel curette, an ultrasonic scaler with steel tips and an air-powder abrasive device with glycine powder applied with nozzles for sub-gingival use. The air-abrasive device provided the highest cleaning efficacy, followed by the ultrasonic device. The major advantage of the tested sub-gingival nozzles is the flexibility. It gives clinicians an easy way to reach peri-implant pockets and implant surfaces, particularly when the access is hindered and the removal of the prosthesis is not possible.

Even if the in-vitro results are encouraging, the in-vivo evidence is still limited. Sahm et al.[28] in a randomized controlled clinical trial showed that the treatment of initial/moderate peri-implantitis with an air-abrasive device with glycine powder could obtain the same PD reduction of carbon curettes and chlorhexidine digluconate. It could also achieve significantly higher BOP reduction. Randomized controlled clinical trials are required to assess the real in-vivo efficacy of air-polishing devices for the resolution of peri-implantitis, focusing on severe cases.

Antibacterial and antiseptic molecules have been proposed to boost the bacterial elimination and to help decontaminate the implant porous surface. Chlorhexidine was shown to be ineffective in peri-implantitis treatment. Porras et al.[29] could not find any PD reduction and only a limited BOP reduction introducing the additional use of local 0.12% chlorhexidine irrigation and gel during the treatment, plus 10 days of 0.12% chlorhexidine mouthrinse.

Figure 7. Pocket decontamination with erythritol powder conveyed by sub-gingival tip.

Figure 8. Implant surface debridement with piezo-ceramic device and PEEK tip.

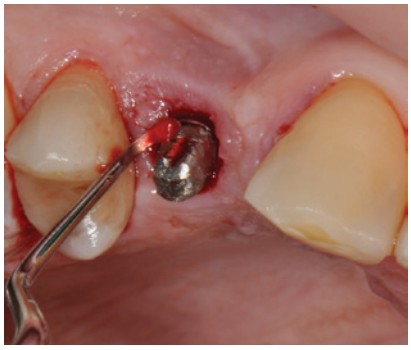

Figure 9. Internal pocket line curettage.

Figure 10. Case 1 - Healing at 6 months after MAINST therapy. PPD has decreased to 2mm. BOP and suppuration are absent.

Figure 11. Case 1 - Healing at 12 months after MAINST therapy.

Use of antibiotics

Antibiotics constitute an alternative option. Since peri-implantitis is a very localised disease, it's not reasonable to take into consideration systemic antibiotic therapy with all the side effects it can bring. It's important to notice that, to date, no controlled clinical trials evaluated the effects of any systemic antibiotic therapy in the treatment of peri-implantitis.[4] On the other hand, locally delivered antibiotics can have a concentrated and strong action, being released in a high dose, in a limited area and for many days. Tetracyclines have been widely investigated in periodontology given their broad action spectre. Mombelli et al.[30] tested a locally delivered 25% tetracycline in the treatment of peri-implantitis. After scaling with plastic curettes, monolithic ethylene vinyl acetate fibers charged with the antibiotic were located around implants and removed after 10 days. Clinical, radiographic and microbiological parameters improved in a good amount of the subjects. Unfortunately, the lack of a control group does not allow an understanding of the real magnitude of the antibiotic action. Furthermore, the authors faced some difficulties in assuring a contact between the fibres and the implant surface, in particular in narrow and deep defects. The use of different biodegradable carriers can give a closer and easier contact with the implant structure with no need for carrier removal. Renvert et al.[31] tested a single dose of locally delivered minocycline as a coadjuvant of manual debridement and compared it to chlorhexidine gel. The additional effect of minocycline on PD and BOP was small but significantly higher than chlorhexidine. Büchter et al.[32] studied the effect of biodegradable slow-release 8.5% doxycycline as an adjunction to debridement with plastic curettes, plus motivation and oral hygiene instructions. The results were promising, showing a significantly greater PD and BOP reduction and mean attachment level gain when doxycycline was used. In conclusion, doxycycline seems to be the most effective local antibiotic available.

Clinical experience with the MAINST treatment protocol

Schwarz et al.[3,33] summarised the most recent evidence about peri-implant disease treatment through plaque removal and adjunctive or alternative measures. Regarding peri-implantitis, a meta-analysis showed that air-polishing for biofilm removal and local antibiotics as a coadjuvant could achieve a higher BOP reduction over the respective control treatments.

Given the promising results reported in scientific literature, we decided to test ourselves the application of air-polishing systems with erythritol powder and a controlled-release 14% doxycycline hyclate local antibiotic (Ligosan®). So far, there is no scientific evidence supporting the efficacy of this coadjuvant.

The tested protocol consisted of a Multiple Anti Infective Non-Surgical Therapy (MAINST) involving the use of topical 14% doxycycline to solve the peri-implantitis acute phase and, after 7 days, a session of Full Mouth Air Polishing Therapy (FM-EPAPT) with erythritol powder (Figure 7) and a piezoceramic device with PEEK-coated tips (Figure 8), curettage of internal pocket line (Figure 9) and a second application of doxycycline. The patients underwent quarterly maintenance sessions, carried out following the same FM-EPAPT steps and were instructed to use personalised home care instruments, such as sonic toothbrushes, interdental brushes, floss and AirFloss (Philips Sonicare AirFloss Ultra).

MAINST key points are:

- To make an initial strong local decontamination though the use of doxycycline, to soothe the acute phase of peri-implantitis without damaging the inflamed soft tissues;

Figure 12. Case 2 - Baseline. Probing reveals a deep PPD with abundant suppuration and BOP.

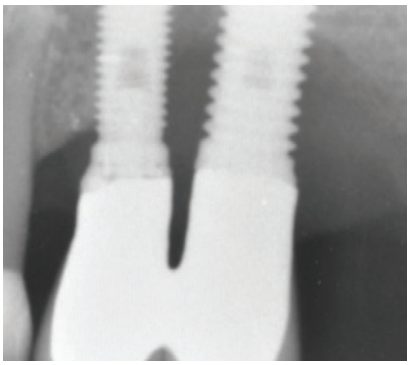

Figure 13. Case 2 - Baseline. The radiography shows severe peri-implant CBL.

Figure 14. Case 2 - First application of doxycycline 14%.

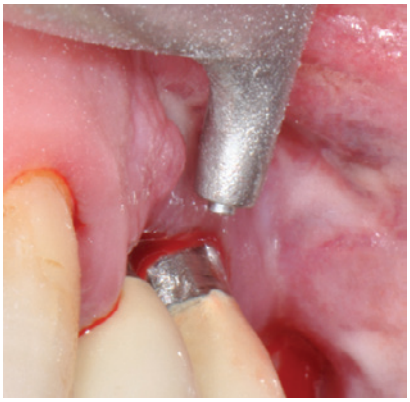

Figure 15. Case 2 - Supra-gingival biofilm removal with erythritol powder.

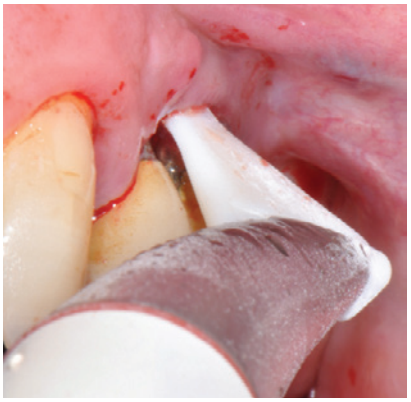

Figure 16. Case 2 - Subgingival decontamination with erythritol powder and sub-gingival tip.

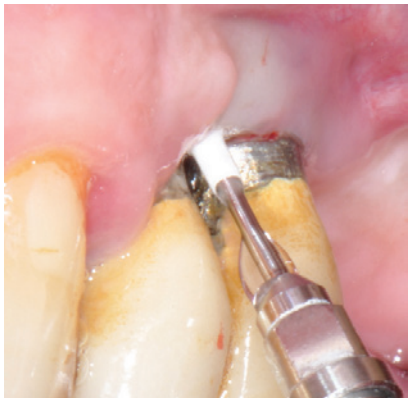

Figure 17. Case 2 - Implant surface debridment with piezo-ceramic device and PEEK tip.

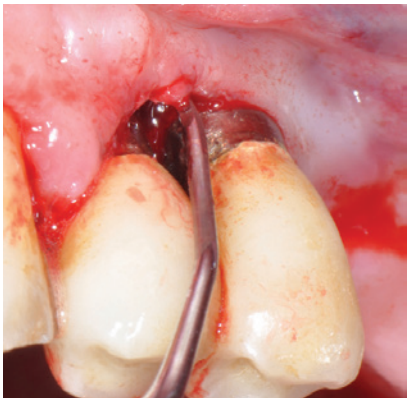

Figure 18. Case 2 - Internal pocket line curettage.

Figure 19. Case 2 - Second application of doxycycline 14%.

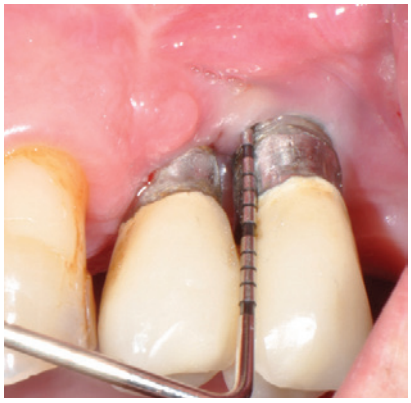

Figure 20. 12 months healing. PPD reduction and BOP absence are noticeable.

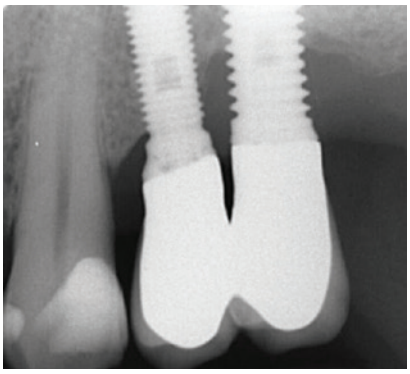

Figure 21. Case 2 - 12 months radiograph.

Figure 22a-b. EMS Air-Flow PLUS Erythritol powder and EMS Perio-Flow sub-gingival tip.

- To carry on a full-mouth decontamination and detoxification phase, using erythritol powder and a piezo-electric device with a PEEK-coated tip (FM-EPAPT) in order to achieve an effective and mini-invasive biofilm and calculus removal;
- To involve the patients in a strict professional maintenance protocol;
- To instruct patients to use an adequate home care routine.

After 12 months, both BOP and mean PD decreased, with a significant gain of clinical attachment. The first case-series of MAINST is waiting to be published with encouraging results. Figure 10 and 11 show the healing at 6 and 12 months after MAINST protocol of the peri-implantitis case displayed at the beginning of this article (Figures 1-4) and Figures 12-21 show a complete MAINST case.

About the authors

Dr Magda Mensi graduated in Dentistry in 2000 with honours and is currently a Professor of Periodontology, Oral Surgery and Implantology at the University of Brescia in Italy. She has been a researcher in Oral Surgery and Periodontology at the University of Brescia since 2002 in addition to serving as a first level medical manager at the Dental Clinic Hospital "Spedali Civili" of Brescia. Her main topics of research include: Low abrasive powders, aggressive periodontitis, antibiotics and delivery systems and peri-implantitis. Dr Mensi completed a Master in Periodontology and Implantology at the University of Ferrara in Italy in 2012 and has been a member of the SidP (Italian Society of Periodontology) since 2001. In 2015, she was a visiting professor at Ohio State University. Furthermore, she has authored several national and international research papers and is a highly sought after speaker.

Dr Annamaria Sordillo graduated in 2016 from the University of Brescia in Italy where she was part of the periodontology research group lead by Prof. Mensi. Her interests include preventive dentistry and oral surgery. She moved to Australia in January 2017 to live with her Australian partner and start a new adventure. Dr Annamaria Sordillo is supporting EMS in Australia and New Zealand as an AIRFLOW Specialist.

References

1. Esposito M, Grusovin MG, Tzanetea E, Piattelli A, Worthington HV. Interventions for replacing missing teeth: treatment of perimplantitis. Cochrane Database of Systematic Reviews, 2010;Issue 6. Art. No.: CD004970. DOI: 10.1002/14651858.CD004970.pub4.
2. Lang NP, Berglundh T on Behalf of Working Group 4 of the Seventh European Workshop on Periodontology: Periimplant diseases: where are we now? – Consensus of the Seventh European Workshop on Periodontology. J Clin Periodontol, 2011;38(Suppl.11):178–181. doi: 10.1111/j.1600-051X.2010.01674.x.
3. Schwarz F, Schmucker A, Becker J. Efficacy of alternative or adjunctive measures to conventional treatment of peri-implant mucositis and peri-implantitis: a systematic review and meta-analysis. Int J Implant Dent. 2015 Dec;1(1):22. Epub 2015 Aug 13.
4. Figuero E, Graziani F, Sanz I, Herrera D, Sanz M. Management of peri-implant mucositis and peri-implantitis. Periodontol 2000, 2014;66: 255–273. doi:10.1111/prd.12049.
5. Heitz-Mayfield LJA. Peri-implant diseases: diagnosis and risk indicators. J Clin Periodontol, 2008;35(Suppl. 8):292–304. doi: 10.1111/j.1600-051X.2008.01275.x.
6. Salvi GE, Lang NP. Diagnostic parameters for monitoring peri-implant conditions. Int J Oral Maxillofac Implants, 2004;19(suppl):116–127.
7. Albrektsson T, Zarb G, Worthington P, Eriksson AR. The long-term efficacy of currently used dental implants: A review and proposed criteria of success. Int J Oral Maxillofac Implants, 1986;1:11–25.
8. Jepsen S, Berglundh T, Genco R, Aass AM, Demirel K, Derks J, Figuero E, Giovannoli JL, Goldstein M, Lambert F, Ortiz-Vigon A, Polyzois I, Salvi GE, Schwarz F, Serino G, Tomasi C, Zitzmann NU. Primary prevention of peri-implantitis: managing peri-implant mucositis. J Clin Periodontol, 2015;42(Suppl. 16):S152–S157. doi: 10.1111/jcpe.12369.
9. Serino G, Turri A, Lang NP. Probing at implants with peri-implantitis and its relation to clinical peri-implant bone loss. Clin Oral Impl Res, 2013;24:91–95 doi: 10.1111/j.1600-0501.2012.02470.x.
10. Derks J, Tomasi C. Peri-implant health and disease. A systematic review of current epidemiology. Journal of Clinical Periodontology, 2015;42:S158—S71.
11. Berglundh, T., Zitzmann, N. U. and Donati, M. Are peri-implantitis lesions different from periodontitis lesions?. Journal of Clinical Periodontology, 2011;38:188–202. doi:10.1111/j.1600-051X.2010.01672.x.
12. Renvert S, Polyzois IN. Clinical approaches to treat peri-implant mucositis and peri-implantitis. Perio 2000, 2015;68(1):369–404.
13. Quirynen M, Abarca M, Van Assche N, Nevins M, van Steenberghe D. Impact of supportive periodontal therapy and implant surface roughness on implant outcome in patients with a history of periodontitis. Journal Clin Periodontol, 2007;34, 805–815.
14. Sanz M, Chapple IL, on behalf of Working Group 4 of the VIII European Workshop on Periodontology. Clinical research on peri-implant diseases: consensus report of Working Group 4. J Clin Periodontol, 2012;39(Suppl. 12):202–206. doi: 10.1111/j.1600-051X.2011.01837.x.
15. Louropoulou A, Slot DE, Van der Weijden F. The effects of mechanical instruments on contaminated titanium dental implant surfaces: a systematic review. Clin Oral Impl Res, 2014:25:1149–1160 doi: 10.1111/clr.12224.
16. Sundfeldt M, Carlsson LV, Johansson CB, Thomsen P, Gretzer C. Aseptic loosening, not only a question of wear: a review of different theories. Acta Orthopaedica, 2006;77: 177–197.
17. Obando-Pereda GA, Fischer L, Stach-Machado DR. Titanium and zirconia particle- induced pro-inflammatory gene expression in cultured macrophages and osteolysis, inflammatory hyperalgesia and edema in vivo. Life Science, 2014;97: 96–106.
18. Bhola R, Bhola SM, Mishra B, Olson DL. Corrosion in titanium dental implants/prostheses - a review. Trends Biomater Artif Organs, 2011;25(1), 34–46.
19. Fretwurst T, Buzanich G, Nahles S, Woelber JP, Riesemeier H, Nelson K. Metal elements in tissue with dental peri-implantitis: a pilot study. Clin Oral Impl Res; 2016;27:1178–1186 doi: 10.1111/clr.12718.
20. Fox SC, Moriarty JD, Kusy RP. The Effects of Scaling a Titanium Implant Surface With Metal and Plastic Instruments: An in Vitro Study. J Perio, 1990;61(8):485–490 doi: 10.1902/jop.1990.61.8.485.
21. Louropoulou A, Slot DE, Van der Weijden F. Influence of mechanical instruments on the biocompatibility of titanium dental implants surfaces: a systematic review. Clin Oral Impl Res, 2015;:841–850. doi: 10.1111/clr.12365.
22. Louropoulou A, Slot DE, van der Weijden F. Titanium surface alterations following the use of different mechanical instruments: a systematic review. Clin Oral Impl Res, 2012;23: 643–658.
23. Bühler J, Amato M, Weiger R, Walter C. A systematic review on the effects of air polishing devices on oral tissues. Int J Dent Hygiene, 2015 DOI:10.1111/idh.12120.
24. Schmage P, Thielemann J, Nergiz I, Scorziello TM, Pfeiffer P. Effects of 10 cleaning instruments on four different implant surfaces. The International Journal of Oral & Maxillofacial Implants, 2012;27: 308–317.
25. Drago L , Del Fabbro M, Bortolin M, Vassena C, De Vecchi E, Taschieri S. Biofilm removal and antimicrobial activity of two different air-polishing powders: an in vitro study. J Periodontol, 2014; Nov;85(11):e363–9. doi: 10.1902/jop.2014.140134. Epub 2014 Jul 25.
26. Schmidt KE, Auschill TM, Heumann C, Frankenberger R, Eick S, Sculean A, Arweiler NB. Influence of different instrumentation modalities on the surface characteristics and biofilm formation on dental implant neck, in vitro. Clin Oral Impl Res 2016;00:1–8.
27. Ronay V, Merlini A, Attin T, Schmidlin PR, Sahrmann P. In vitro cleaning potential of three implant debridement methods. Simulation of the non-surgical approach. Clin Oral Impl Res, 2016;00:1–6 doi: 10.1111/clr.12773.
28. Sahm N, Becker J, Santel T, Schwarz F. Non-surgical treatment of peri-implantitis using an air-abrasive device or mechanical debridement and local application of chlorhexidine: a prospective, randomized, controlled clinical study. J Clin Periodontol, 2011;38: 872–878.
29. Porras R, Anderson GB, Caffesse R, Narendran S, Trejo PM. Clinical response to 2 different therapeutic regimens to treat peri-implant mucositis. J Perio, 2002;73, 1118–1125.
30. Mombelli A, Feloutzis A, Brägger U, Lang NP. Treatment of peri-implantitis by local delivery of tetracycline. Clinical, microbiological and radiological results. Clin Oral Impl Res, 2001;12: 287–294.
31. Renvert S, Lessem J, Dahlén G, Lindahl C, Svensson M. Topical minocycline microspheres versus topical chlorhexidine gel as an adjunct to mechanical debridement of incipient peri-implant infections: a randomized clinical trial. J Clin Periodontol 2006; 33: 362–369. doi: 10.1111/j.1600-051X.2006.00919.x.
32. Büchter A, Meyer U, Kruse-Losler B, Joos U, Kleinheinz J. Sustained release of doxycycline for the treatment of peri-implantitis: randomised controlled trial. Br J Oral Maxillofac Surg, 2004;42: 439–444.
33. Schwarz F, Becker K, Renvert S. Efficacy of air polishing for the non-surgical treatment of peri-implant diseases: a systematic review. J Clin Periodontol 2015; 42: 951–959. doi:10.1111/jcpe.12454.